Anatomy & Physiology of Mood Disorders

Teodor Huzij DO FACN
Medical Director, Trinity Institute

AAO Convocation
March 2016

Disclosures

- No Industry Relationships
- American Osteopathic Board of Neurology and Psychiatry, Board Member
- Anatomical images: Thieme Collection
- Convo 2014- Last lecture on Last Day

Objectives

- 1. Review Mood Disorder criteria and statistics
- 2. Review Anatomy and Physiology related to current evidence for mood disorders
- 3. Review literature for manual medicine with mood disorders

Criteria & Stats

DSM 5 Changes

- No longer a single Mood Disorder chapter
- Now Separated:
  - Depressive Disorders
  - Bipolar and Related Disorders
  - Nomenclature changes

Why These Disorders?

- Major Depressive Disorder and Bipolar I Disorder as Prototypes
- Depressive Disorders
  - Major Depressive D/O, Disruptive Mood Dysregulation D/O, Persistent Depressive D/O, Premenstrual Dysphoric D/O, Unspecified Depressive D/O
- Bipolar and Related Disorders
  - Bipolar I D/O, Bipolar II D/O, Cyclothymic D/O, Unspecified Bipolar and Related D/O

Major Depressive D/O

- Depressed mood OR Anhedonia
- 2wks or more
- 5 or more of the following 9:

- Depressed mood
- Sleep Changes
- ↓Interest/Anhedonia
- Guilty/Worthless
- ↓Energy
- ↓Concentration
- Appetite Changes
- Psychomotor ↑↓
- Suicidality

DSM 5

MDD: Statistics

- Lifetime prevalence 16%, 1yr Incidence 8%
- M:F 1:2

DSM 5. Kessler, JAMA, 2003:289;23.

Bipolar I Disorder

- Manic Episode Criteria (Required for Bipolar I)
- Duration 1 wk
- Euphoric mood: 3 of 7, Irritable mood: 4 of 7

- Distractibility
- Impulsivity/High risk activities
- Grandiosity
- Flight of ideas
- Increased goal directed activity
- Decreased need for sleep
- Increased talkativeness

DSM 5

Bipolar I: Statistics

- Lifetime prevalence 1%, 1yr Incidence 0.6%
- M:F 1:1
- Suicide Lifetime Risk 15x general public
- Episodes: Mania:Depressive - 1:5

DSM 5

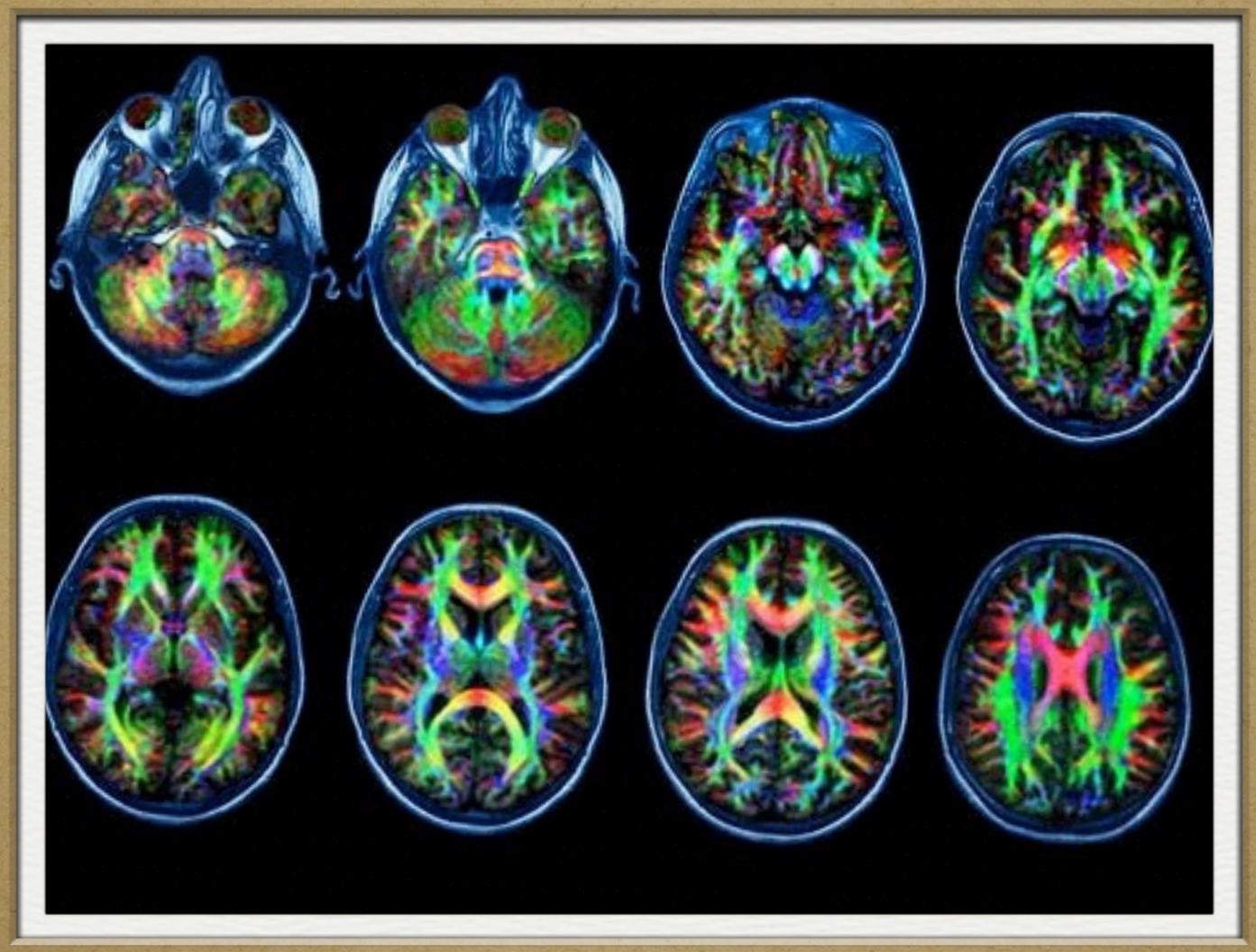

Literature Review

Neuroanatomty & Neurophysiology of Mood Disorders

Caveat & Perspective

- No clear evidence for Etiology in Mood Disorders (Cause/Effect)
- Association at best

HPA & BDNF in MDD

- HPA Axis
  - ↑Cortisol (DST- Sens 64%, Spec 59%)
  - Impaired translocation intracellularly
  - ↓Neuroplasticity
- BDNF
  - ↓BDNF associated with ↓volume
    (Amygdala, Ant Cing Gyrus, Prefrontal Cortex)

Nelson 1997. De Kloet 1998. Pariante 2001. Castren 2010.

GI Microbiota & Brain "Psychobiotics"

- SCFA-Producing Bacteria: → ↓Intestinal & BBB permeability →↓Bacterial translocation
- Diet ↑ Saturated Fat/Processed Food→↑Intestinal Permeability
- ↑Intestinal Permeability→Bacterial translocation ~ possible etiology chronic low-grade inflammation
- No studies in Depression, Animal evidence only

Kelly 2015

GI Microbiota & Brain

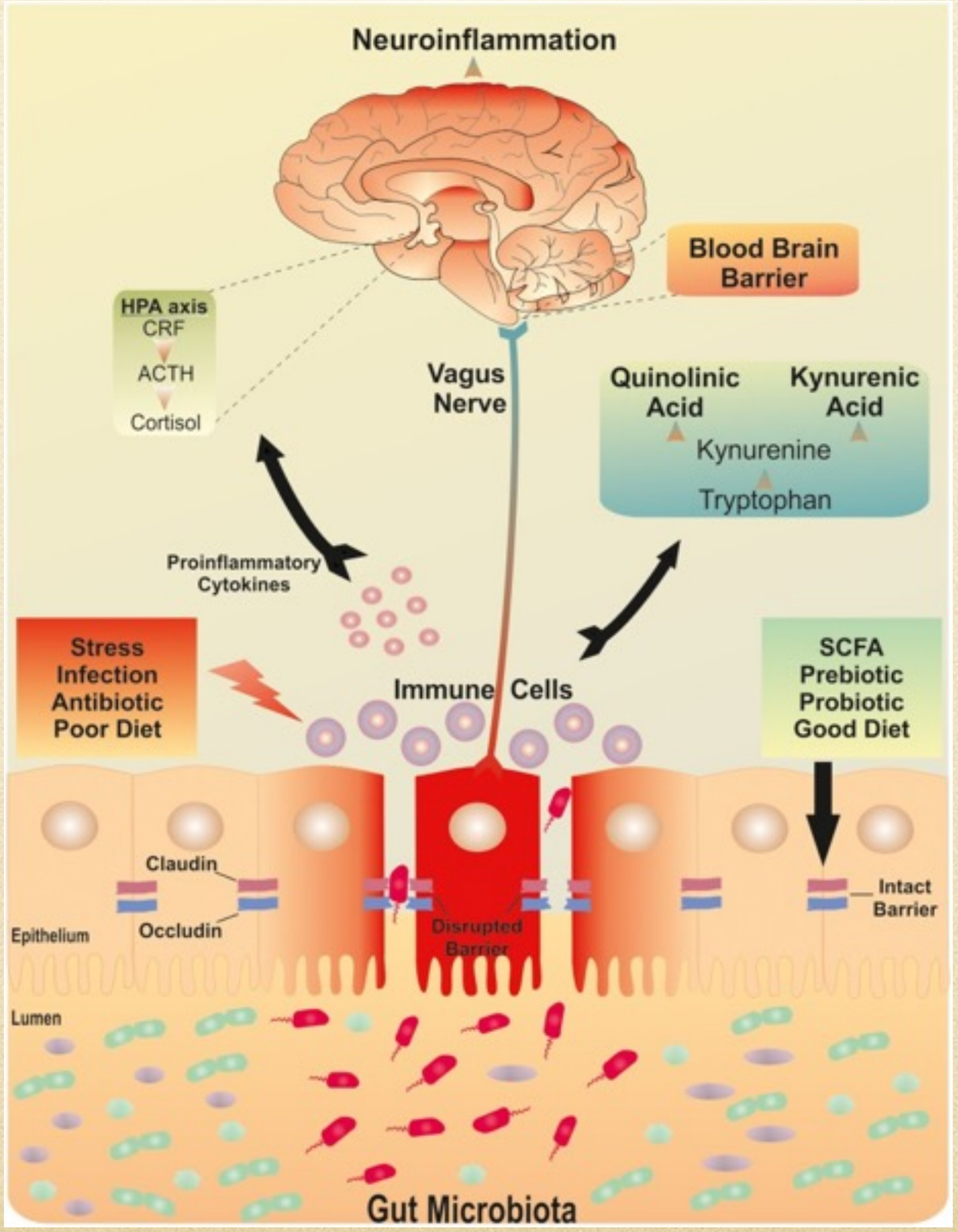

Kelly 2015

MDD: Findings Vary

- Reduced Frontal Lobe volume
- Reduced Caudate
- Reduced Putamen
- Reduced CBF Anterior Cingulate Gyrus
- Increased CBF Medial Orbital Cortex
- Increased CBF Left Amygdala & Medial Thalamus
- Increased CBF Cerebellar Vermis
- Amygdala-Medial-Thalamus-Ventral-Prefrontal Cortex
- Limbic-Striatal-Pallidal-Thalamic

Ebert 1996, Soares 1997, Drevets 1998, Daroff 2012

MDD: Most Evidence

- Hypoperfusion Dorsolateral/Dorsomedial Prefrontal Cortex
- Reduced Frontal Lobe volume
- Hypoperfusion of Anterior Cingulate Gyrus
- Increased CBF Medial Thalamus

Coffey 1993, Ito 1996, Ebert 1996, Soares 1997, Drevets 1998, Daroff 2012

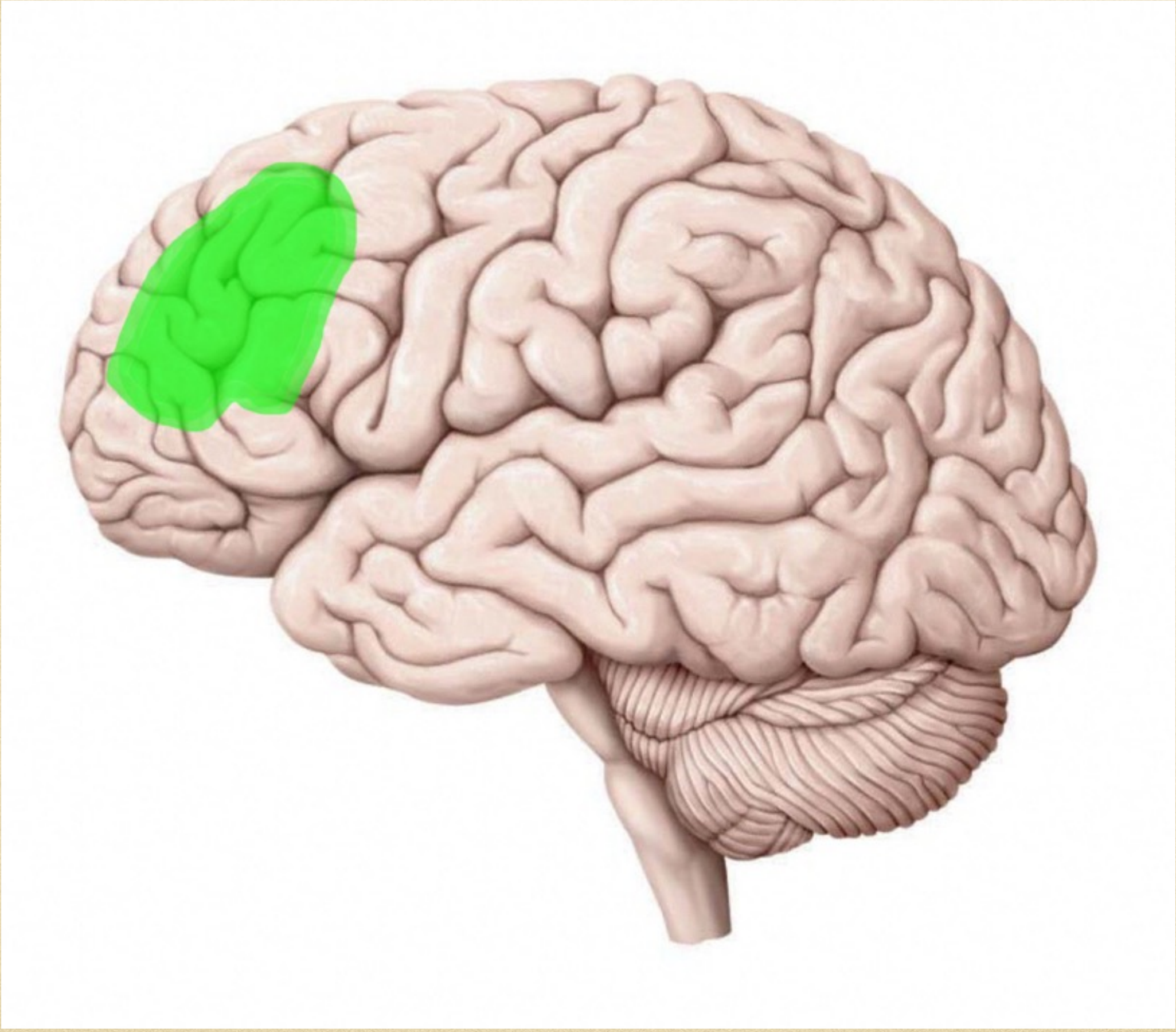

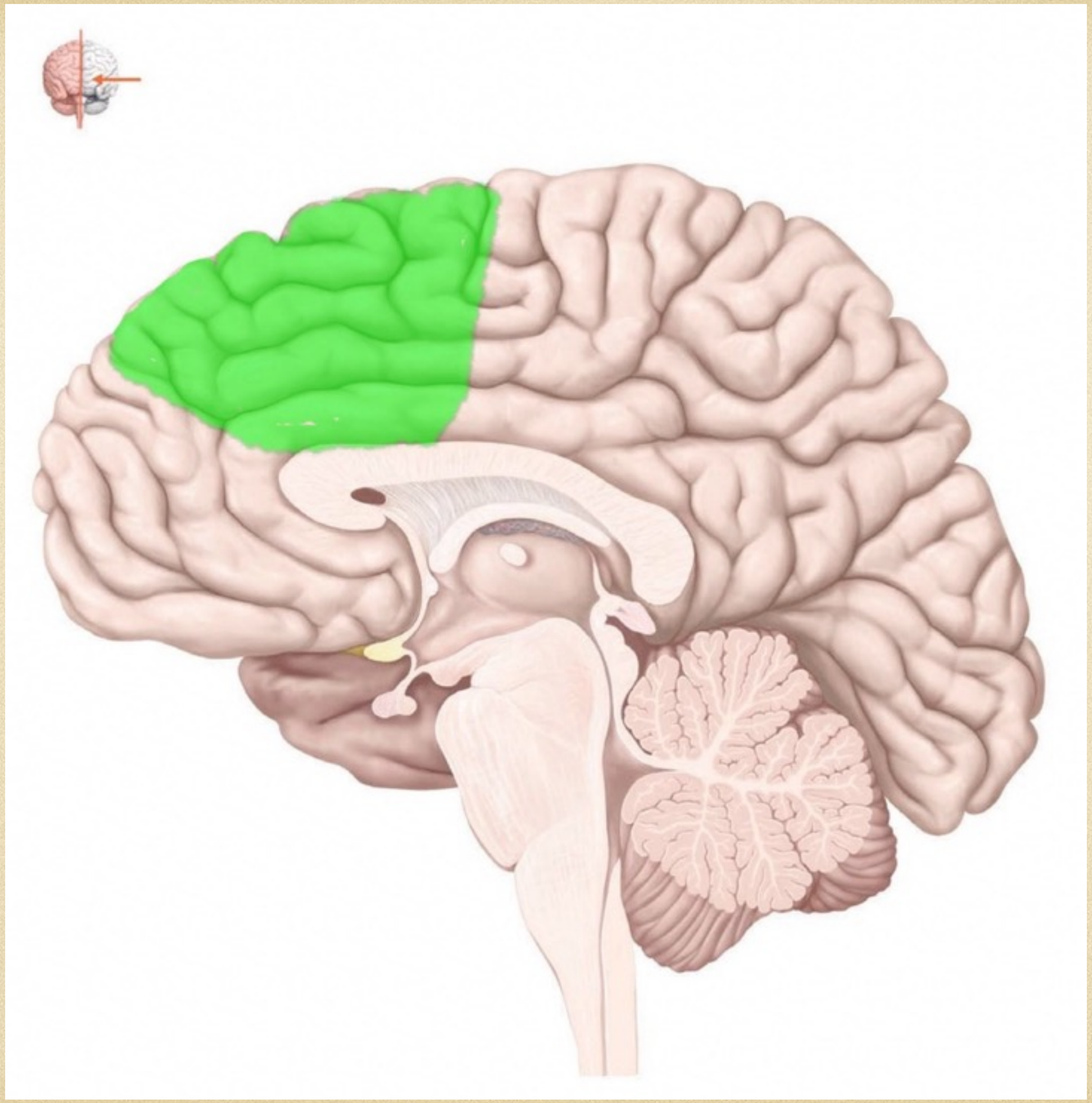

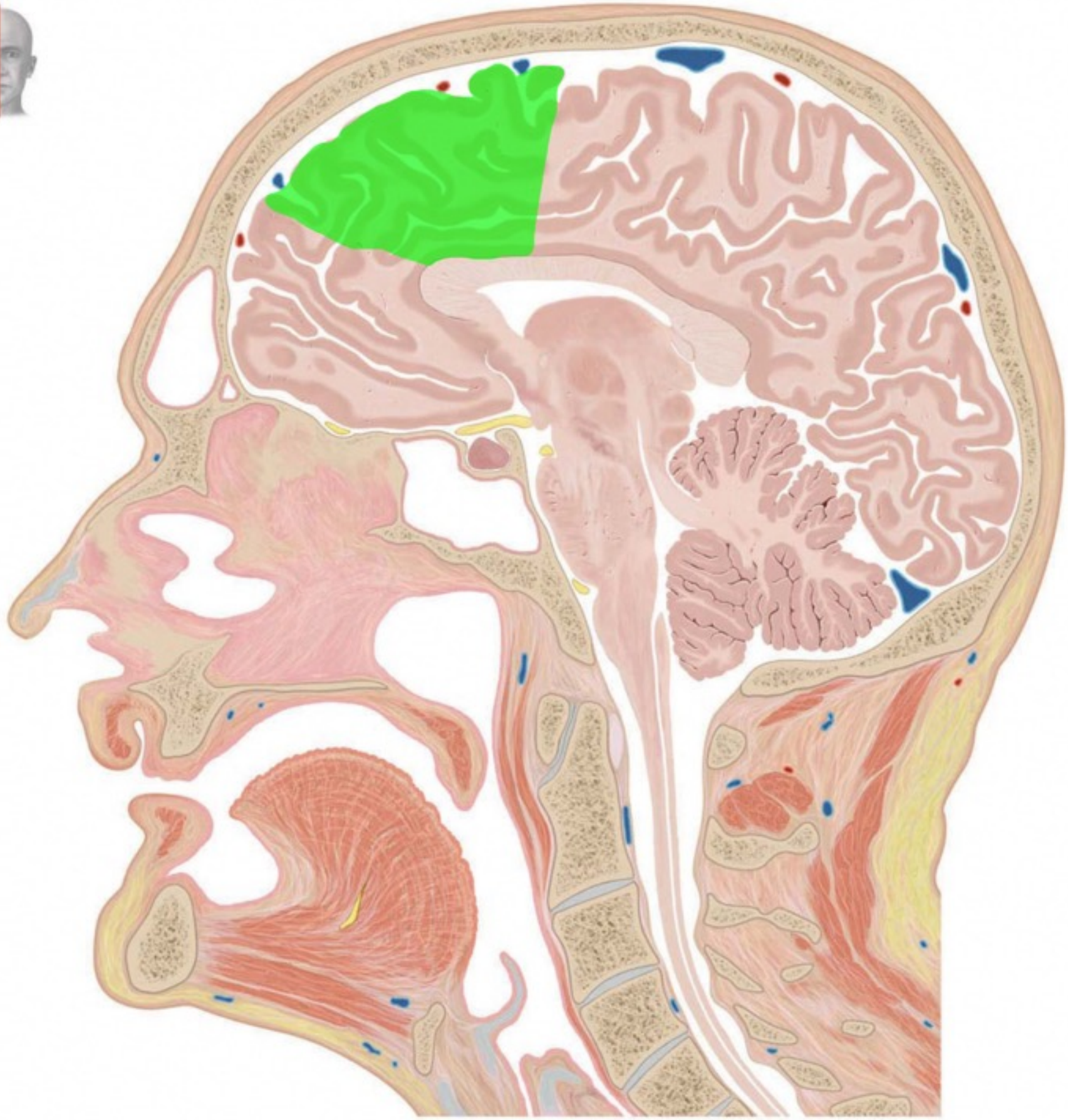

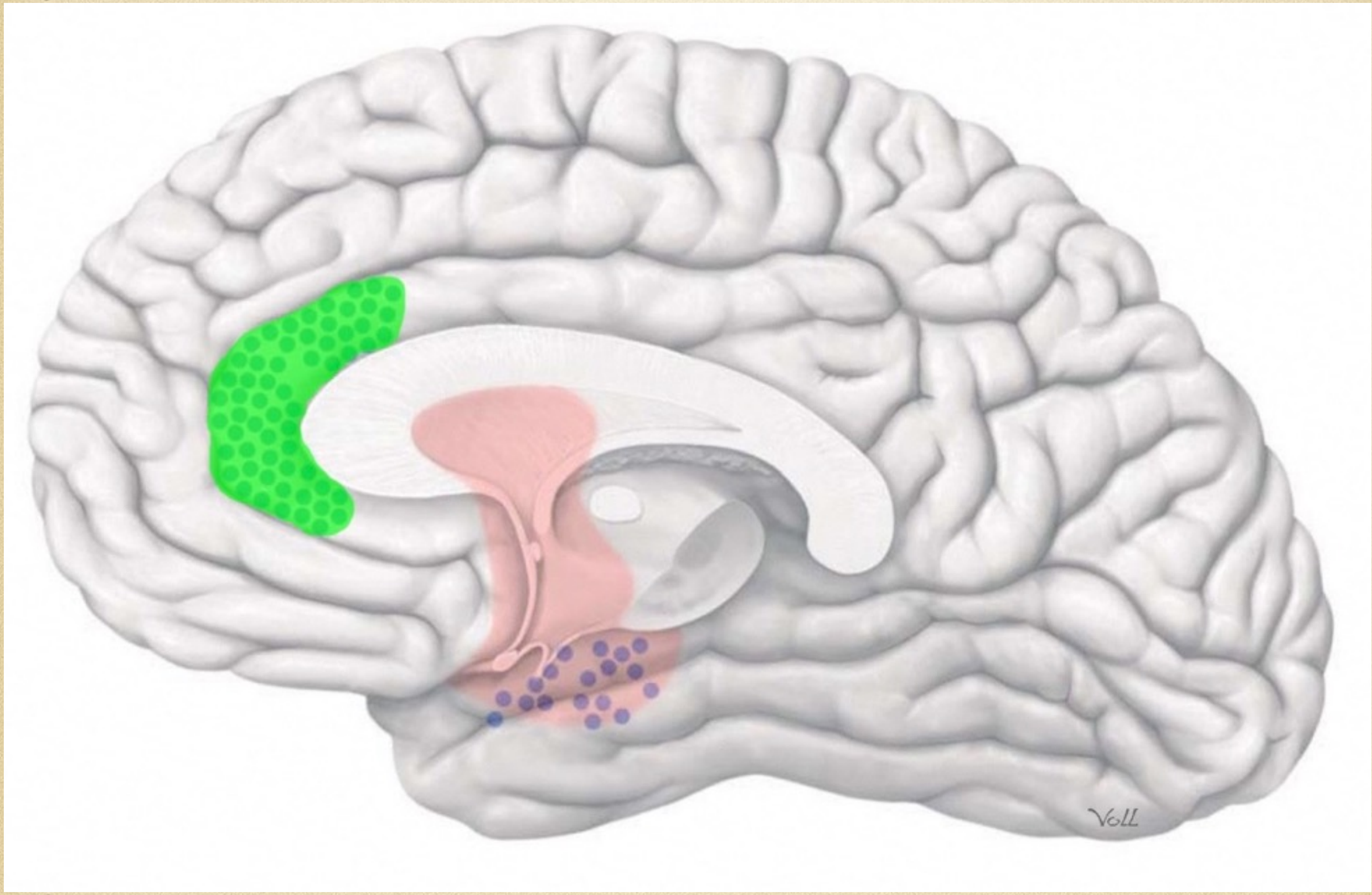
VoLL

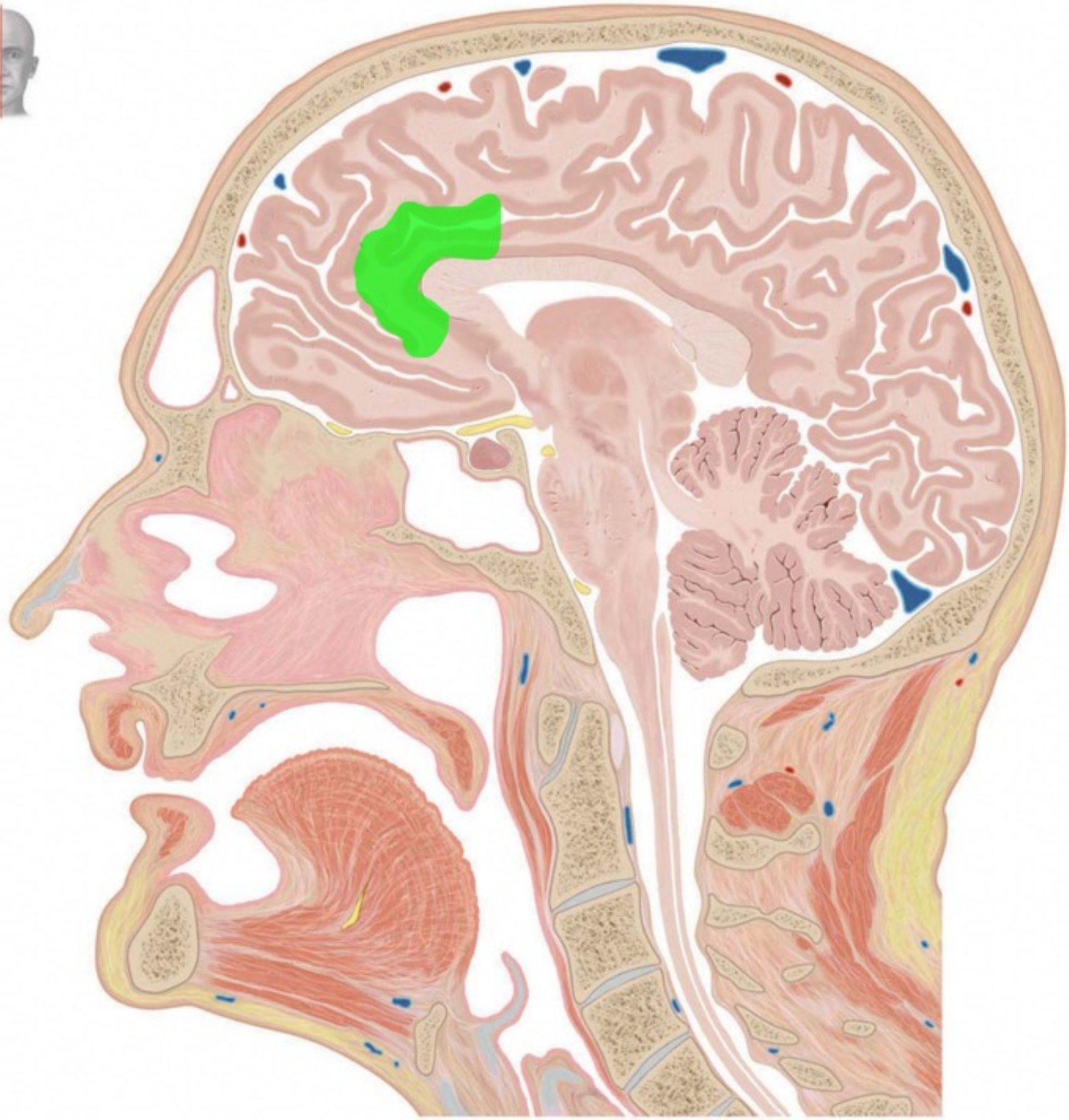

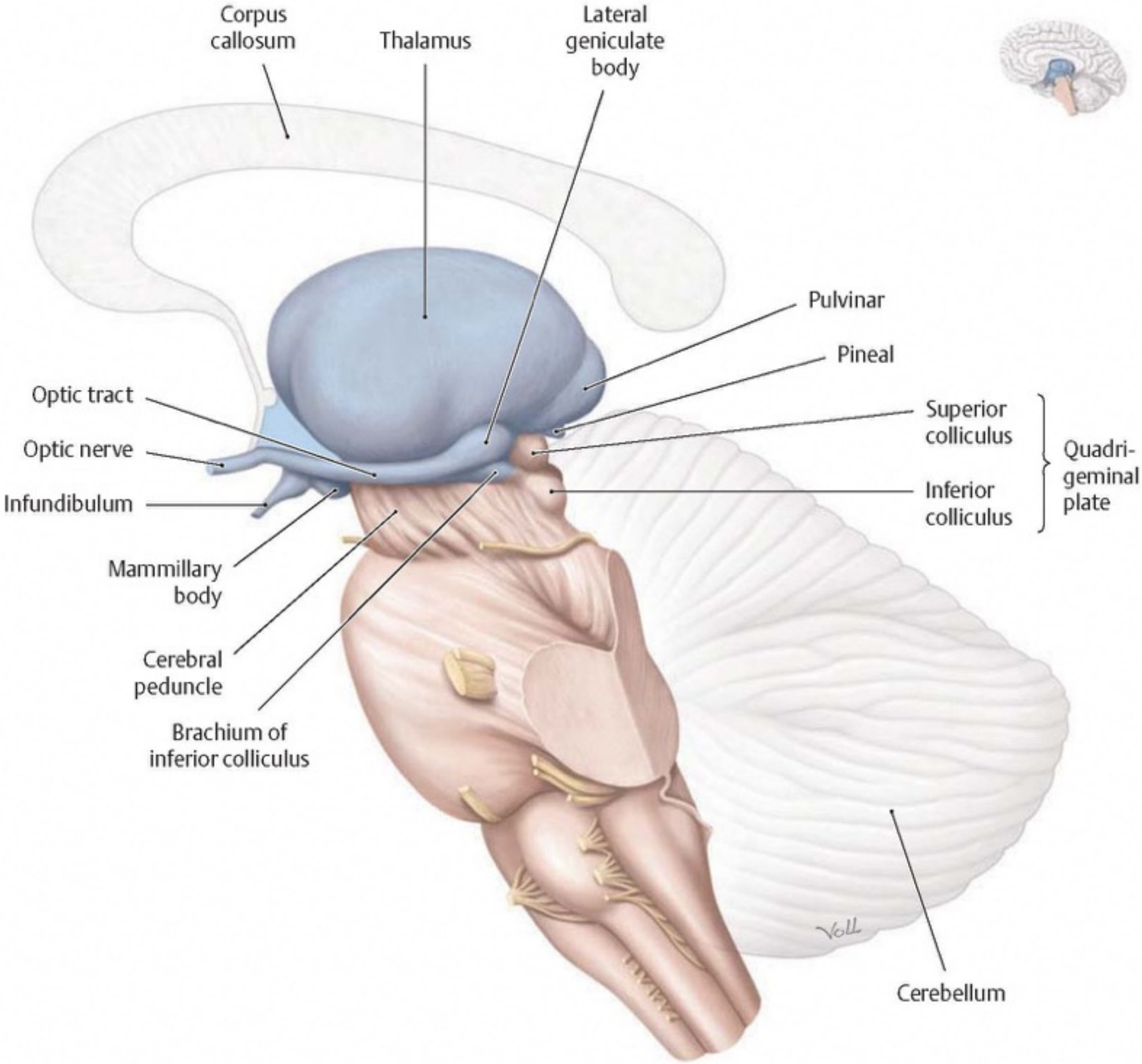
Corpus callosum
Thalamus
Lateral geniculate body
Pulvinar
Pineal
Optic tract
Optic nerve
Infundibulum
Superior colliculus
Inferior colliculus
Quadri-geminal plate
Mammillary body
Cerebral peduncle
Brachium of inferior colliculus
Cerebellum

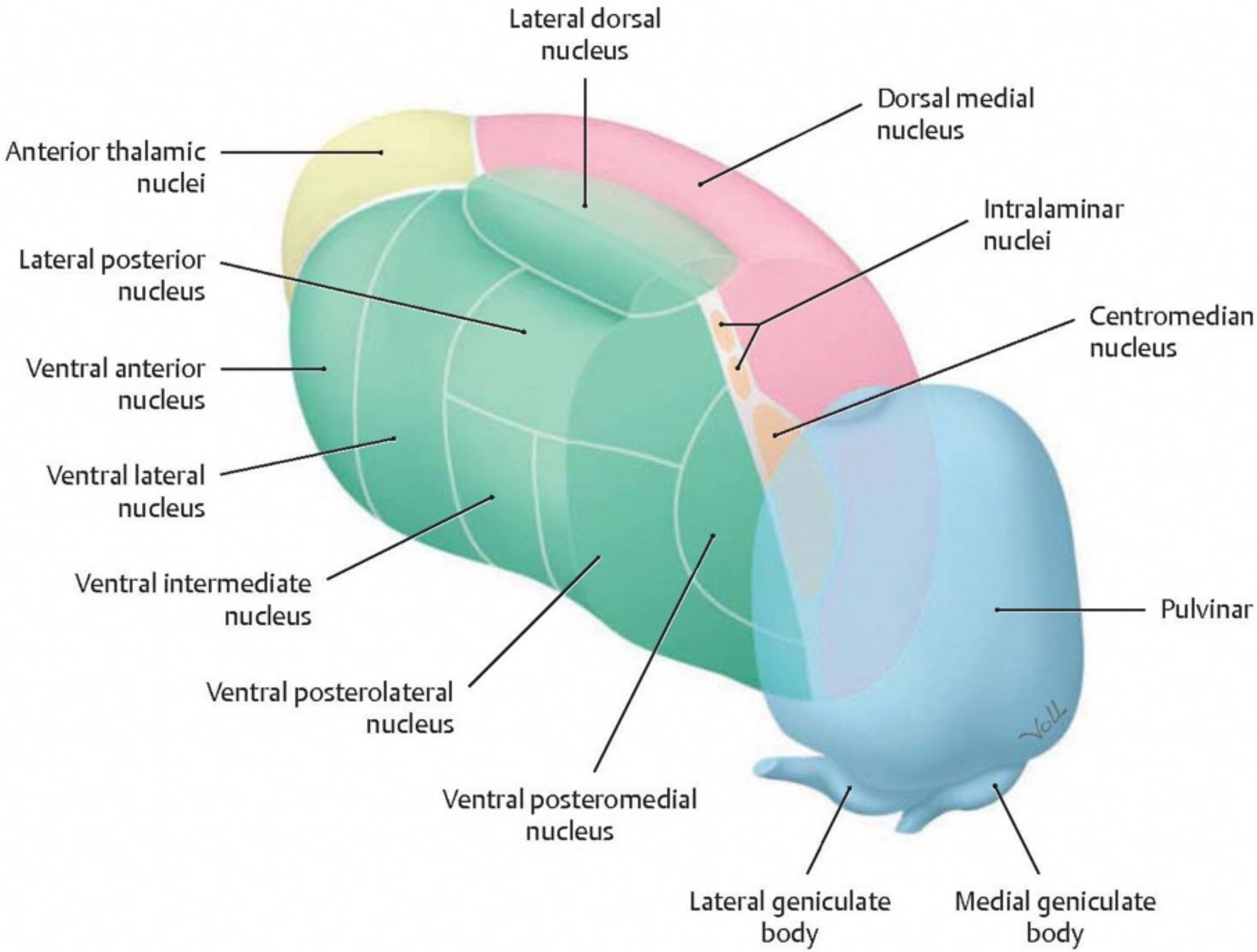
Lateral dorsal nucleus
Dorsal medial nucleus
Anterior thalamic nuclei
Intralaminar nuclei
Lateral posterior nucleus
Centromedian nucleus
Ventral anterior nucleus
Ventral lateral nucleus
Ventral intermediate nucleus
Pulvinar
Ventral posterolateral nucleus
Ventral posteromedial nucleus
Lateral geniculate body
Medial geniculate body

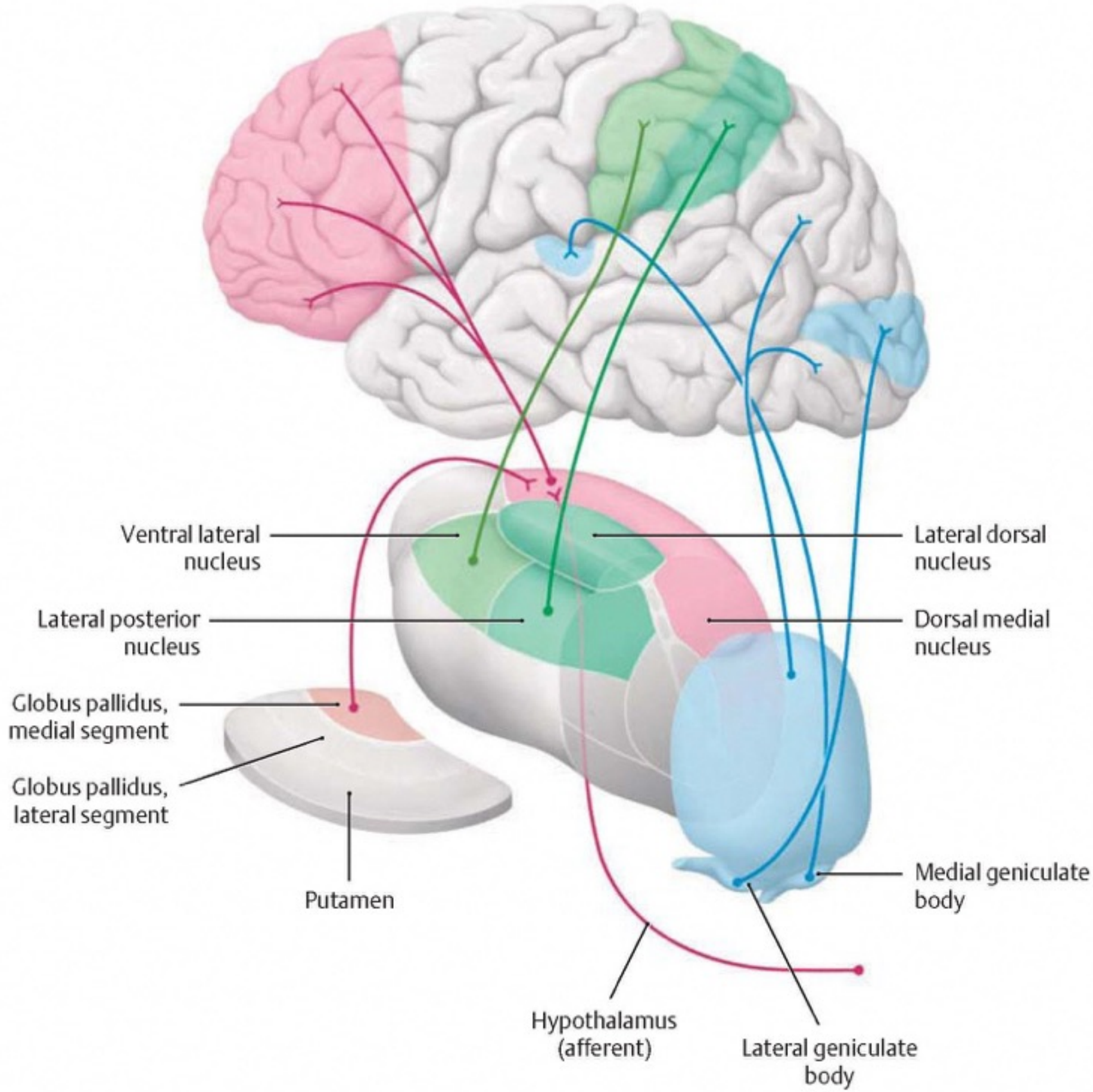
Ventral lateral nucleus
Lateral dorsal nucleus
Lateral posterior nucleus
Dorsal medial nucleus
Globus pallidus, medial segment
Globus pallidus, lateral segment
Putamen
Medial geniculate body
Hypothalamus (afferent)
Lateral geniculate body

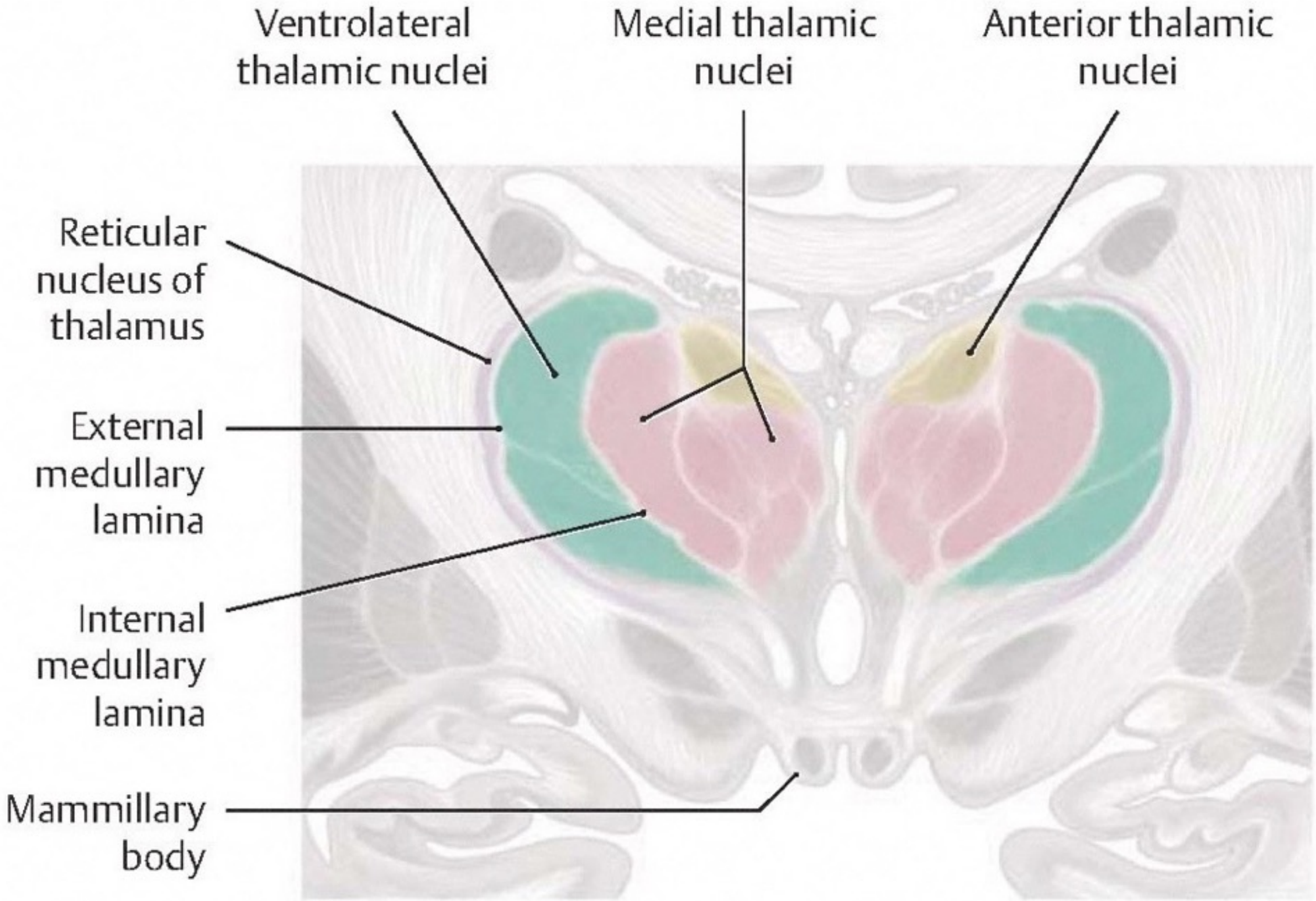
Ventrolateral thalamic nuclei
Medial thalamic nuclei
Anterior thalamic nuclei
Reticular nucleus of thalamus
External medullary lamina
Internal medullary lamina
Mammillary body

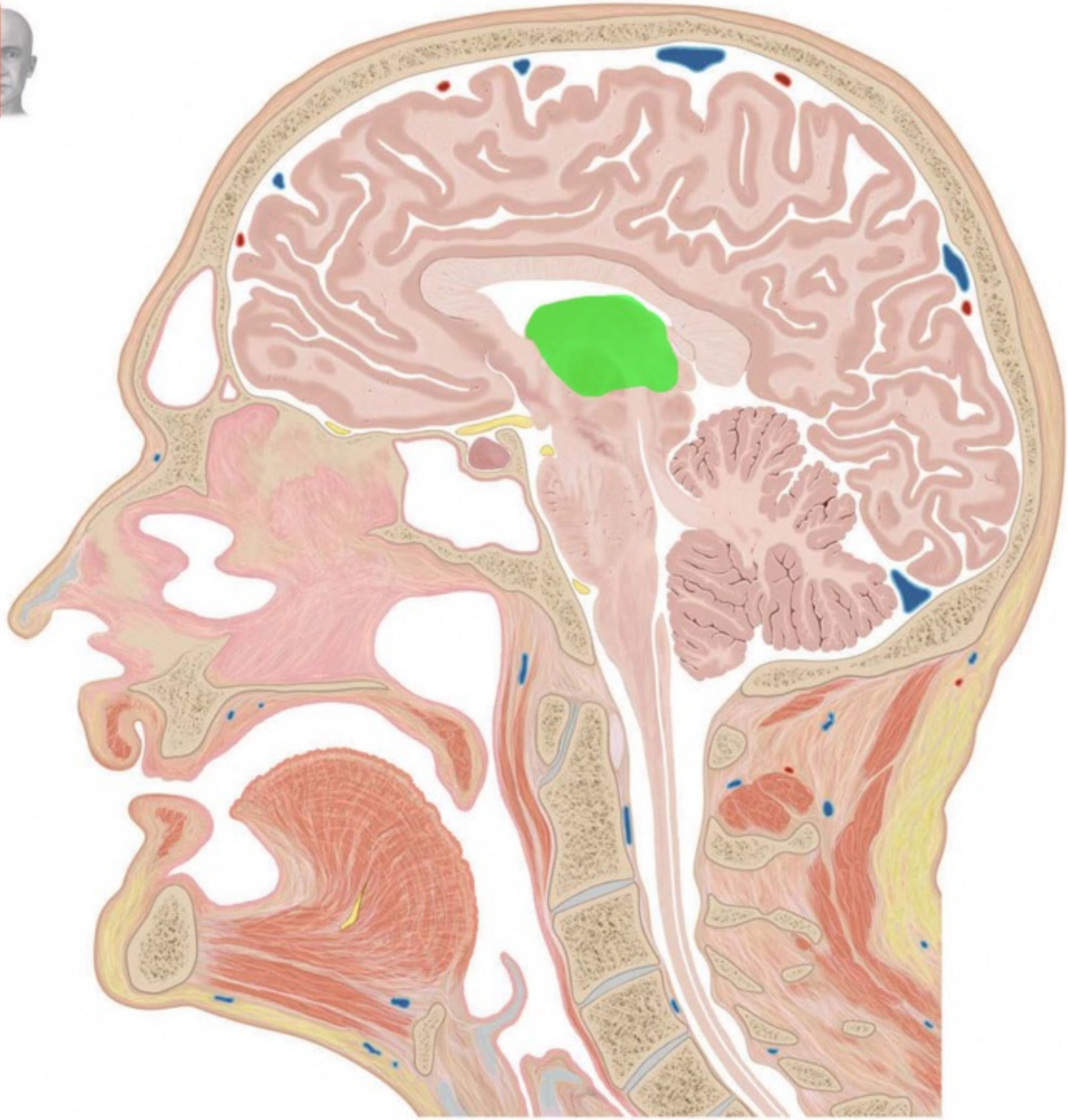

Bipolar: Findings Vary

- Bilateral anterior frontal
- Anterior cingulate gyrus
- Left superior temporal
- Bilateral anterior insular
- Third ventricle
- Cerebellar vermis
- Inferior prefrontal
- Amygdala
- Striatum
- Hippocampus

Ito 1996, Soares 1997, Strakowski 2004, DelBello 2004, Lyoo 2006, William 2007, Ellison-Wright 2010

Bipolar: Most Evidence

- Decreased CBF and Decreased Left Superior Temporal Cortex Volume
- Reduced Right Anterior Cingulate Gyrus Volume
- Reduced Insular Cortex Volume
- Increased Striatum Volume
- Reduced Cerebellar Vermis Volume

Ito 1996, Soares 1997, Strakowski 2004, DelBello 2004, Lyoo 2006, William 2007, Ellison-Wright 2010

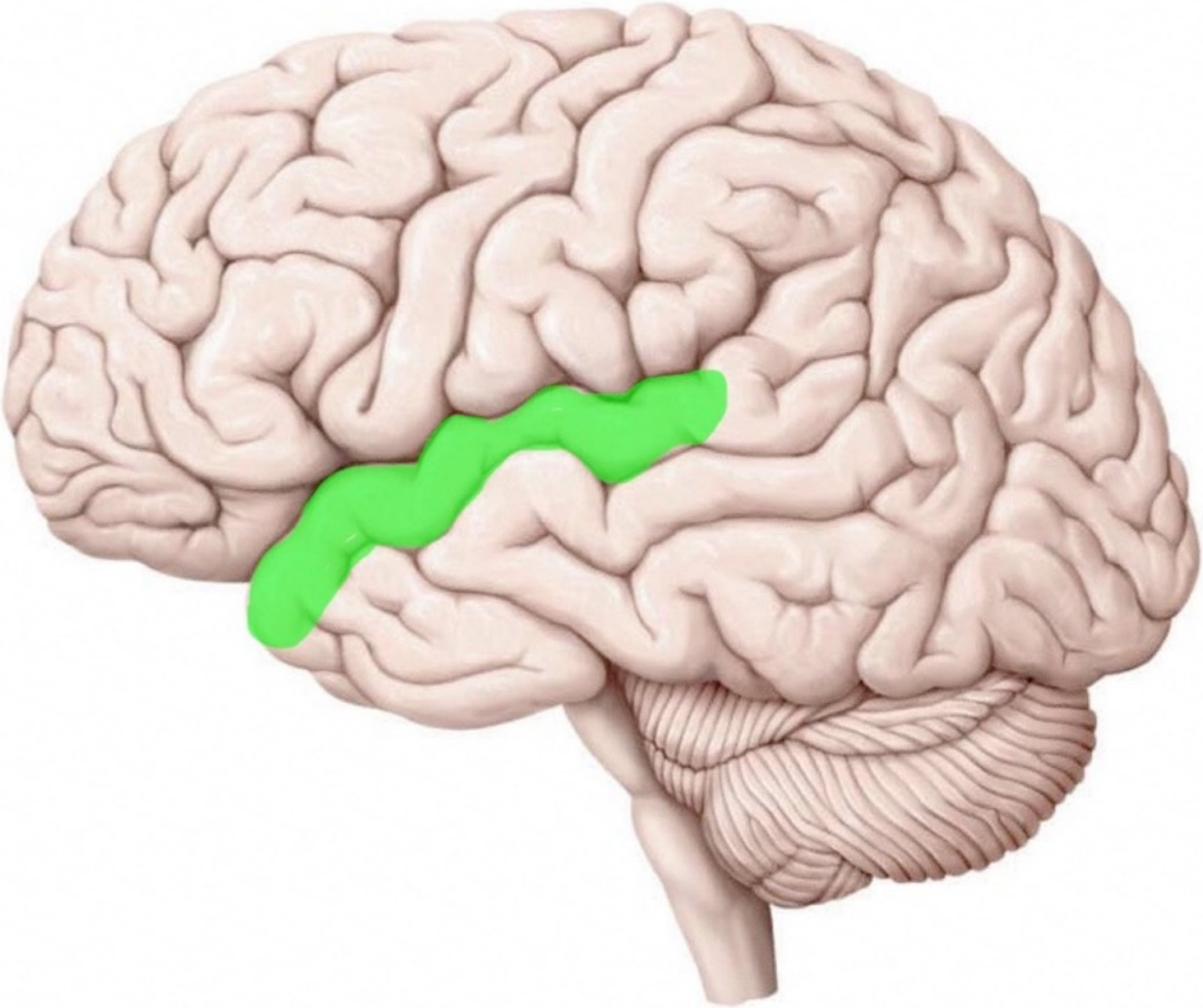

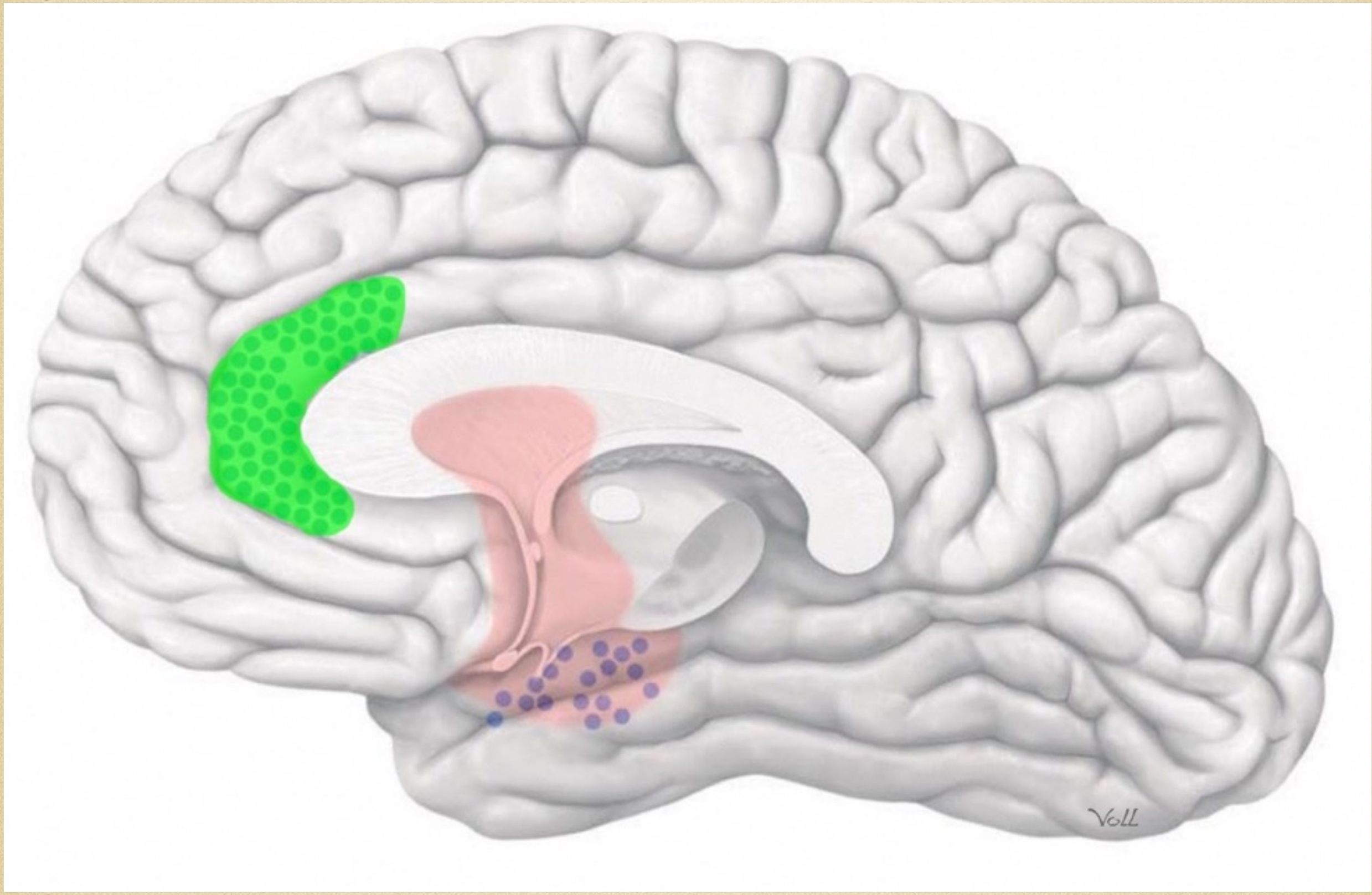
VoLL

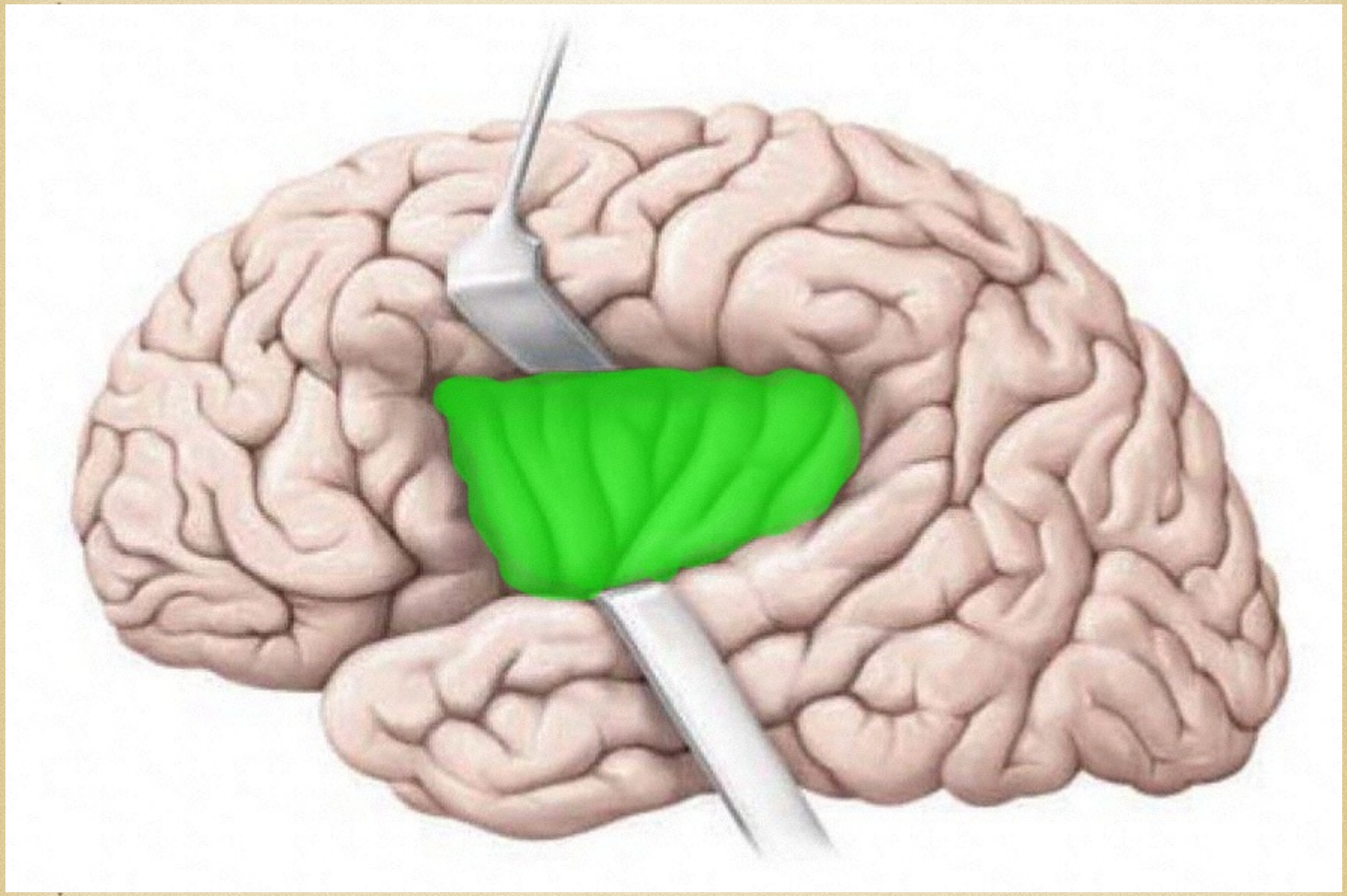

Frontal lobe

Longitudinal cerebral fissure

Interventricular foramina (of Monro)

Insular cortex

Third ventricle

Thalamus

Crura of fornix

Caudate nucleus, tail

Corpus callosum, splenium

Posterior forceps

Occipital lobe

Lateral ventricle, anterior horn

Caudate nucleus, head

Internal capsule, anterior limb

Internal capsule, genu

Globus pallidus

Putamen

External capsule

Claustrum

Extreme capsule

Internal capsule, posterior limb

Choroid plexus of lateral ventricle

Lateral ventricle, posterior horn

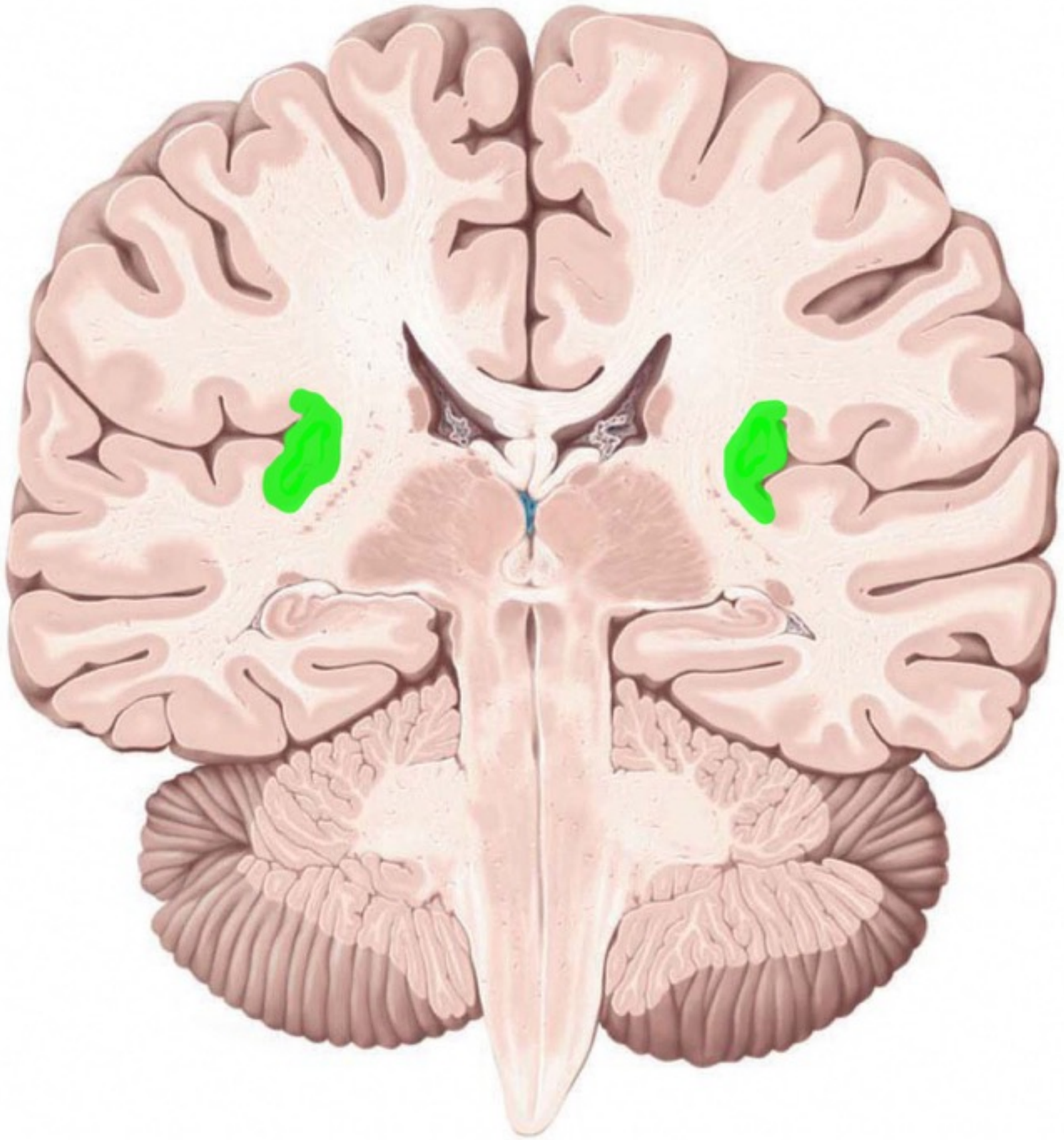

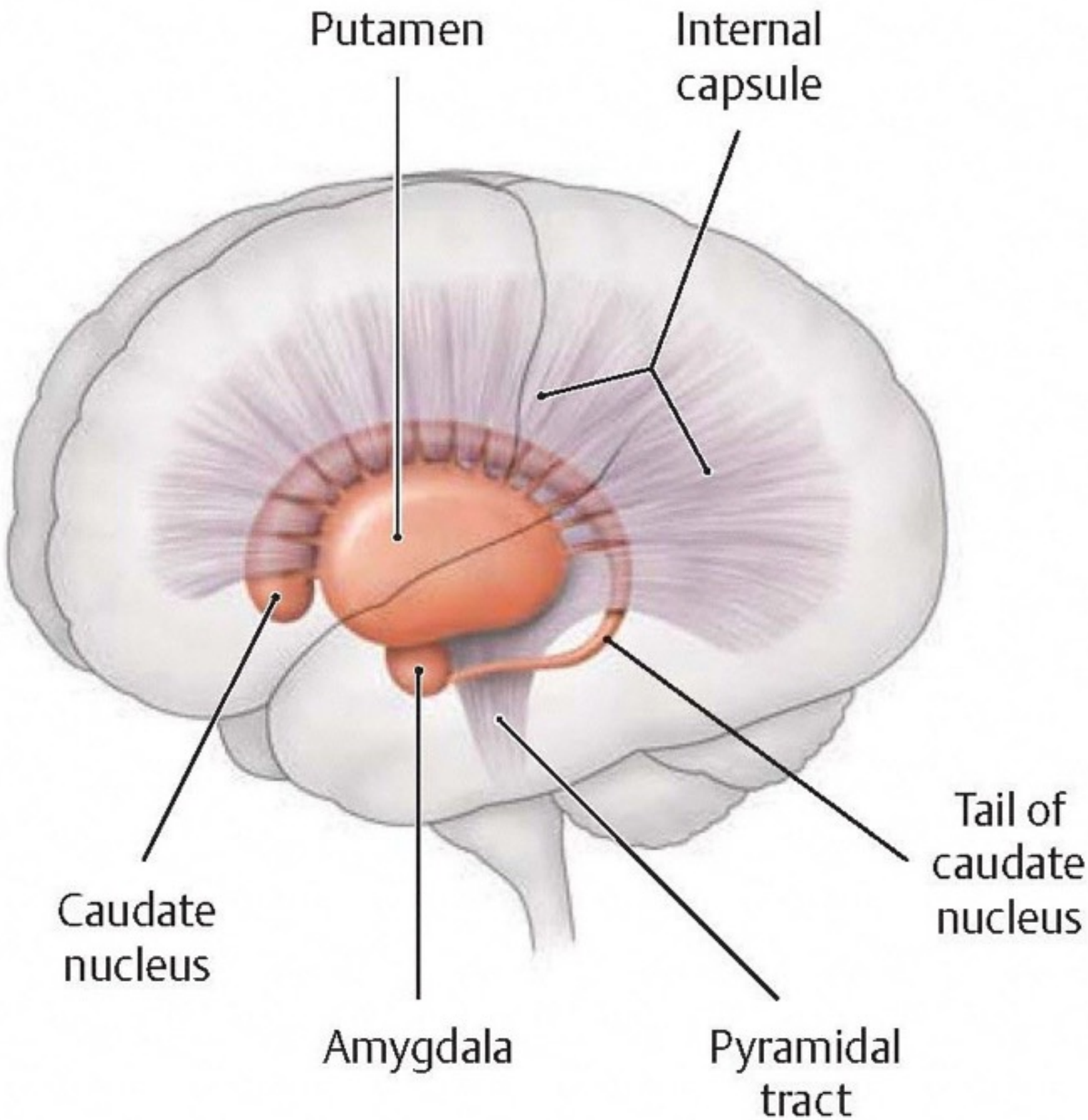
Putamen
Internal capsule
Caudate nucleus
Amygdala
Pyramidal tract
Tail of caudate nucleus

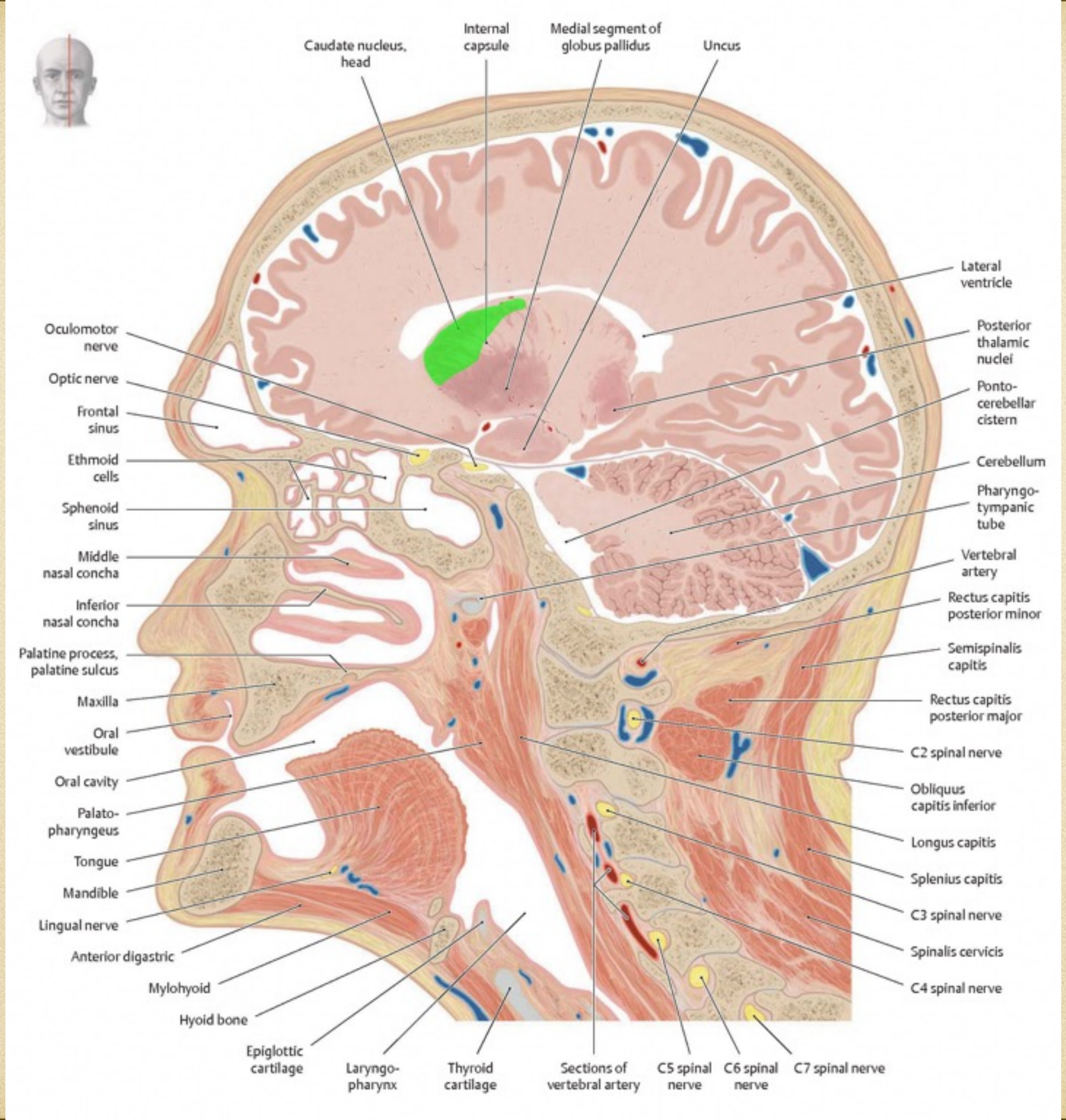
Caudate nucleus, head
Internal capsule
Medial segment of globus pallidus
Uncus
Lateral ventricle
Posterior thalamic nuclei
Ponto-cerebellar cistern
Cerebellum
Pharyngo-tympanic tube
Vertebral artery
Rectus capitis posterior minor
Semispinalis capitis
Rectus capitis posterior major
C2 spinal nerve
Obliquus capitis inferior
Longus capitis
Splenius capitis
C3 spinal nerve
Spinalis cervicis
C4 spinal nerve
Oculomotor nerve
Optic nerve
Frontal sinus
Ethmoid cells
Sphenoid sinus
Middle nasal concha
Inferior nasal concha
Palatine process, palatine sulcus
Maxilla
Oral vestibule
Oral cavity
Palato-pharyngeus
Tongue
Mandible
Lingual nerve
Anterior digastric
Mylohyoid
Hyoid bone
Epiglottic cartilage
Laryngo-pharynx
Thyroid cartilage
Sections of vertebral artery
C5 spinal nerve
C6 spinal nerve
C7 spinal nerve

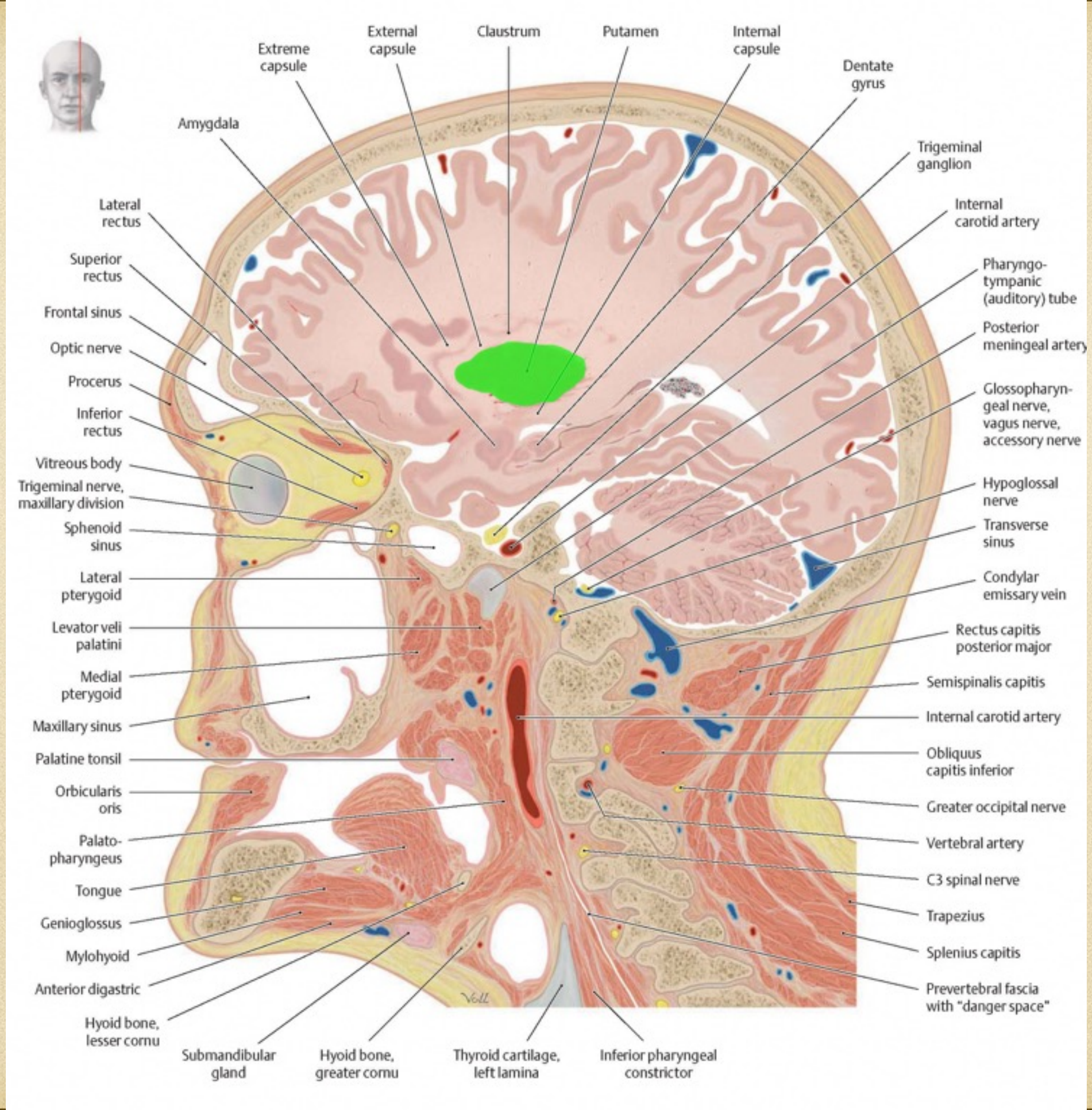
Extreme capsule
External capsule
Claustrum
Putamen
Internal capsule
Dentate gyrus
Amygdala
Trigeminal ganglion
Lateral rectus
Internal carotid artery
Superior rectus
Pharyngo-tympanic (auditory) tube
Frontal sinus
Posterior meningeal artery
Optic nerve
Procerus
Glossopharyngeal nerve, vagus nerve, accessory nerve
Inferior rectus
Vitreous body
Hypoglossal nerve
Trigeminal nerve, maxillary division
Transverse sinus
Sphenoid sinus
Condylar emissary vein
Lateral pterygoid
Rectus capitis posterior major
Levator veli palatini
Semispinalis capitis
Medial pterygoid
Internal carotid artery
Maxillary sinus
Obliquus capitis inferior
Palatine tonsil
Orbicularis oris
Greater occipital nerve
Palato-pharyngeus
Vertebral artery
Tongue
C3 spinal nerve
Genioglossus
Trapezius
Mylohyoid
Splenius capitis
Anterior digastric
Prevertebral fascia with "danger space"
Hyoid bone, lesser cornu
Submandibular gland
Hyoid bone, greater cornu
Thyroid cartilage, left lamina
Inferior pharyngeal constrictor


Caudate nucleus
Lateral ventricle
Putamen
Olfactory tract
Corpus callosum
Internal capsule
External capsule
Claustrum
Extreme capsule
b

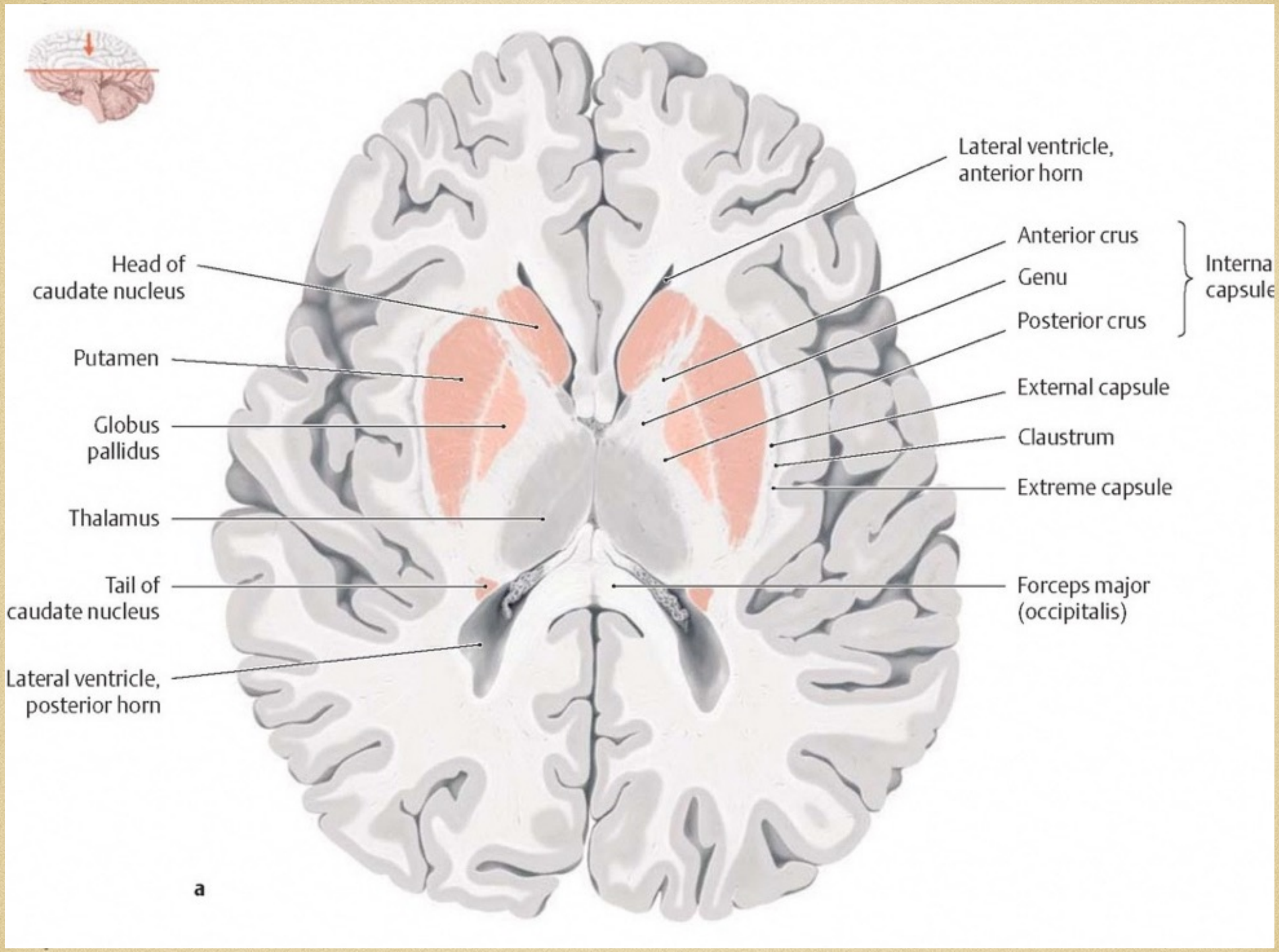
Lateral ventricle, anterior horn
Anterior crus
Genu
Posterior crus
Interna capsule
Head of caudate nucleus
Putamen
External capsule
Globus pallidus
Claustrum
Extreme capsule
Thalamus
Tail of caudate nucleus
Forceps major (occipitalis)
Lateral ventricle, posterior horn
a

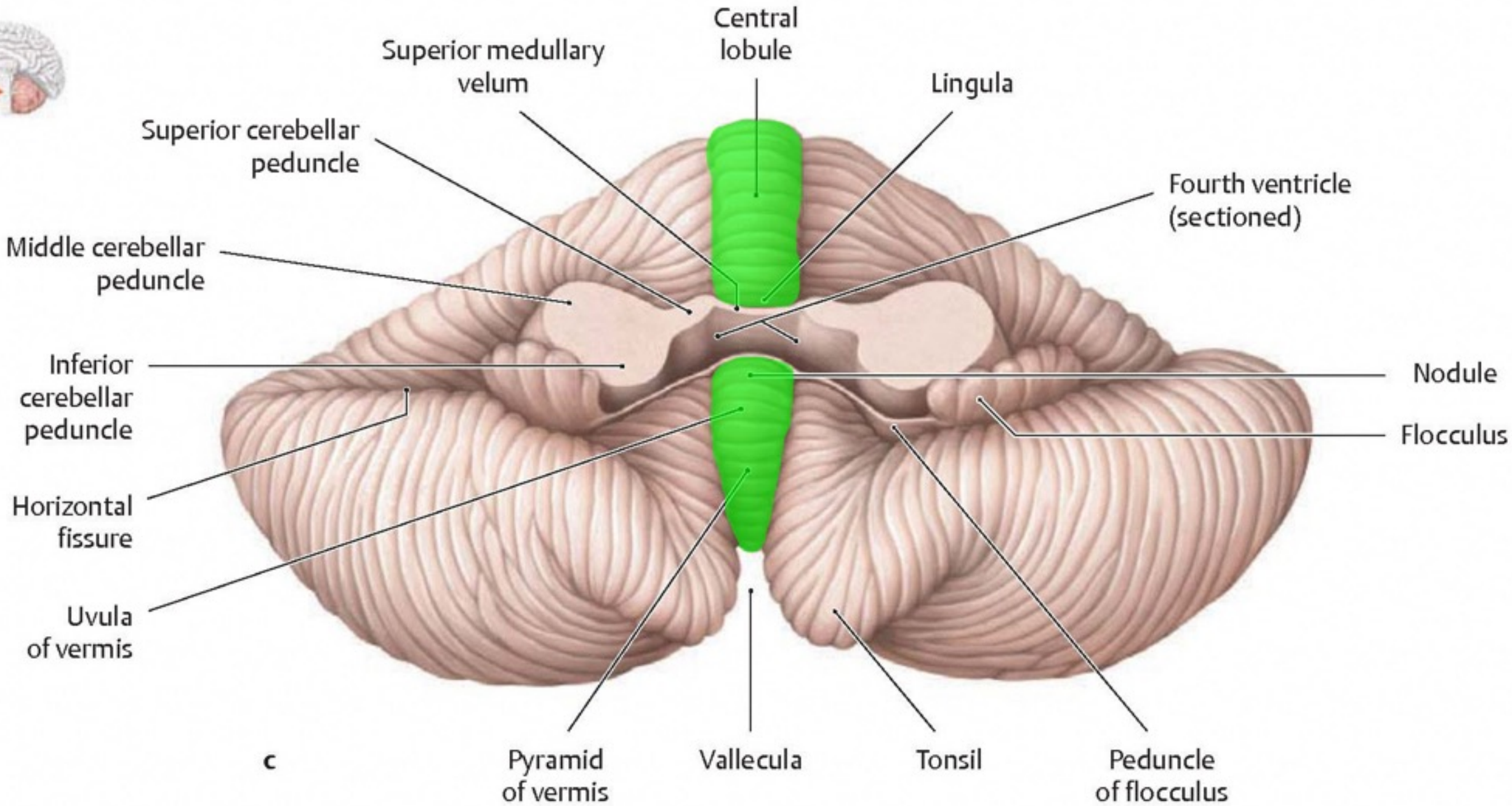
Central lobule
Superior medullary velum
Lingula
Superior cerebellar peduncle
Fourth ventricle (sectioned)
Middle cerebellar peduncle
Inferior cerebellar peduncle
Nodule
Flocculus
Horizontal fissure
Uvula of vermis
c
Pyramid of vermis
Vallecula
Tonsil
Peduncle of flocculus

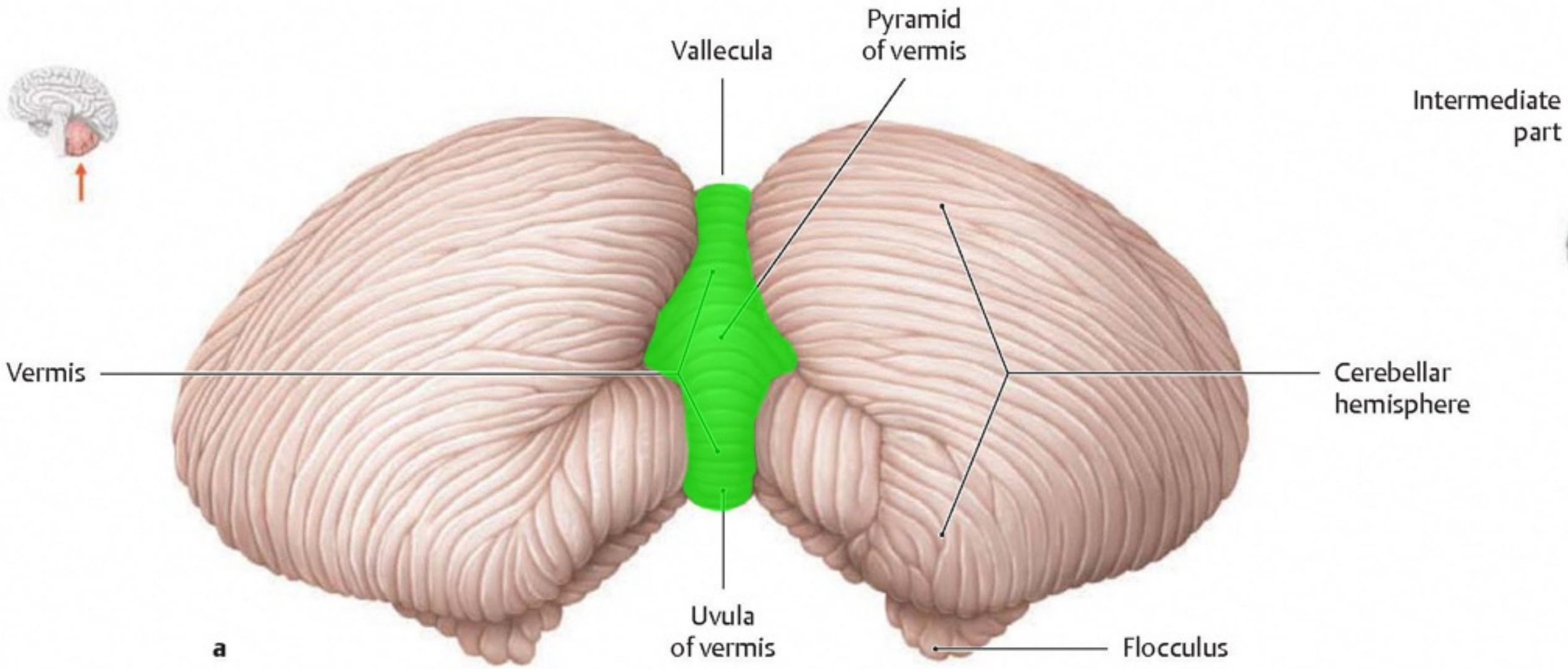
Vallecula
Pyramid of vermis
Intermediate part
Vermis
Cerebellar hemisphere
Uvula of vermis
Flocculus
a

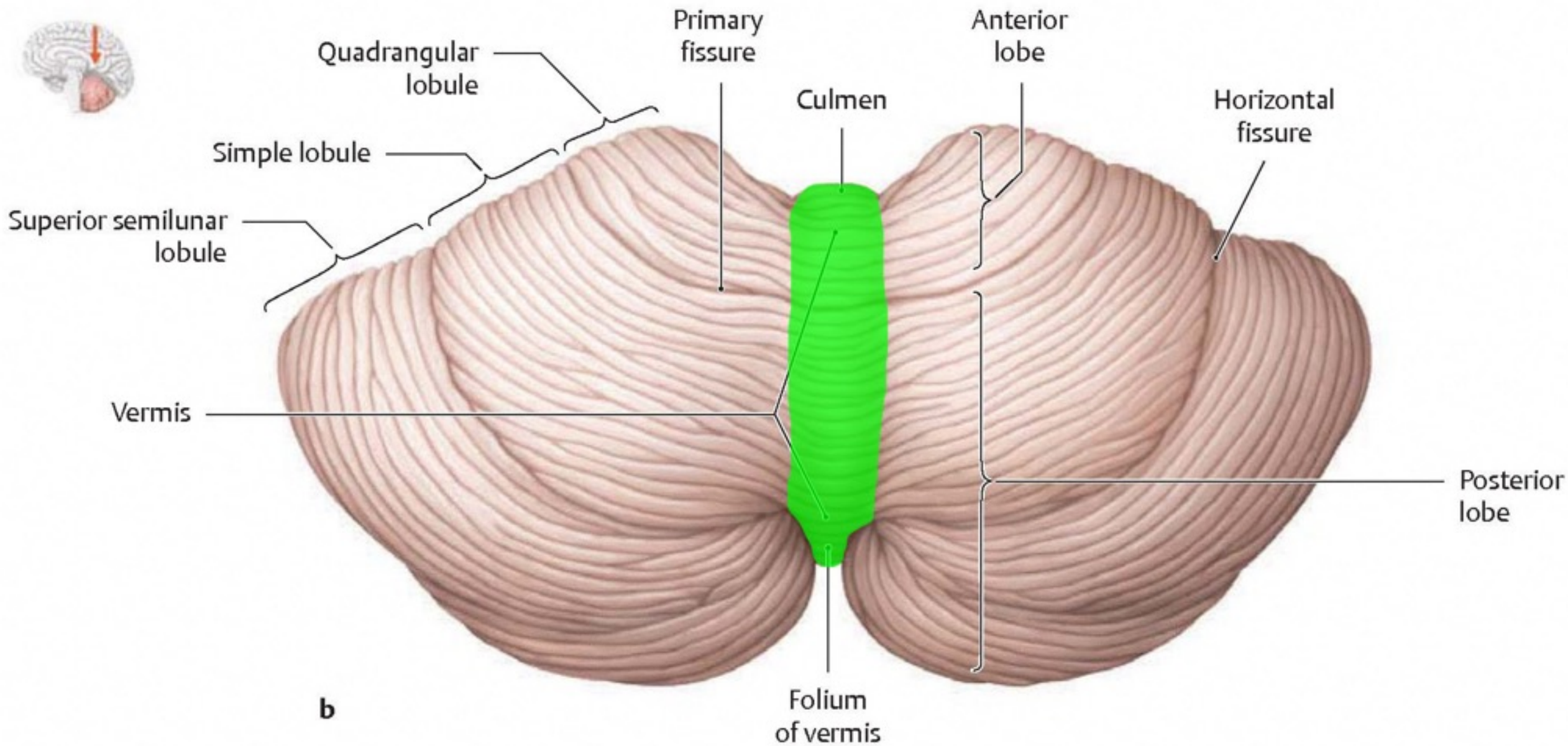
Quadrangular lobule
Simple lobule
Superior semilunar lobule
Vermis
Primary fissure
Culmen
Anterior lobe
Horizontal fissure
Posterior lobe
Folium of vermis
b

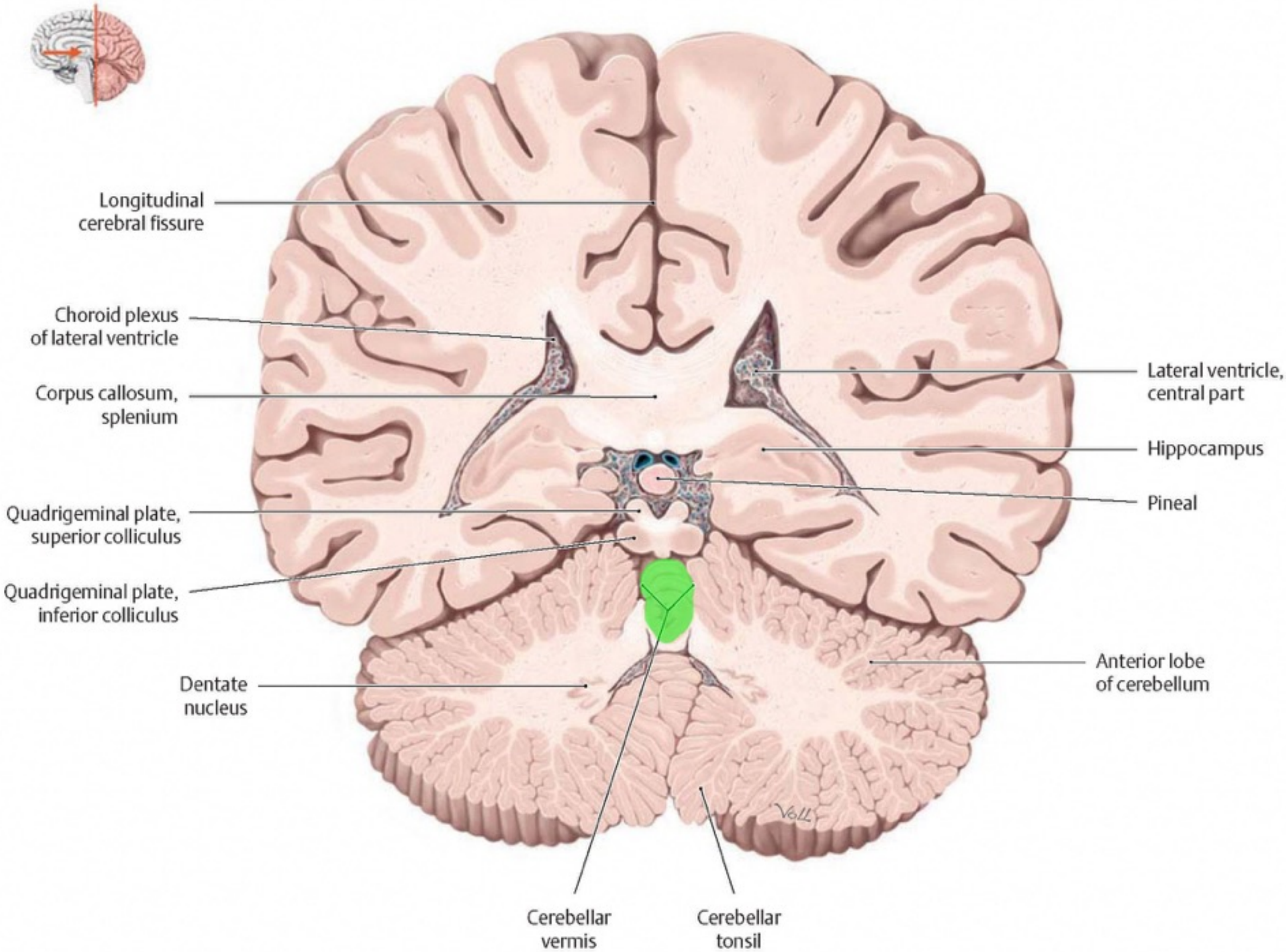
Longitudinal cerebral fissure
Choroid plexus of lateral ventricle
Corpus callosum, splenium
Quadrigeminal plate, superior colliculus
Quadrigeminal plate, inferior colliculus
Dentate nucleus
Cerebellar vermis
Cerebellar tonsil
Lateral ventricle, central part
Hippocampus
Pineal
Anterior lobe of cerebellum

An Osteopathic Perspective

- Body is a Unit
- Each element is reciprocally interrelated
- Are Changes Pathologic or Physiologic
- Seeking Health in each element

An Osteopathic Perspective

- Structure & Function Reciprocally Interrelated
  - ↑↓ Perfusion:
    - Vascular tone ~ Fluid dynamics
  - Volumetric changes:
    - Pathologic STR ⇄ Pathologic FNX
  - Activation level:
    - Pathologic vs Compensatory

An Osteopathic Perspective

- Self-healing & Self-regulatory Systems
  - ↑↓ Perfusion:
    - Physiologic blood dynamics vs Pathology
  - Volumetric changes:
    - Don’t use it you lose it
  - Activation level:
    - Resting strained areas, Conserving resources

An Osteopathic Perspective

- Guiding Discernment
- Osteopathic Principles as a Lens
- Trust & Rely on Innate Wisdom of Body Unit
- Seek Health, Continually



Literature Review

Manual Medicine & Mental Health

Overall

- Search terms included: “depression”, “major depressive disorder”, “dysthymic disorder”, “dysthymia”, “bipolar”, “manic depression”, “mood disorder”, “manual medicine”, “osteopathic”, “osteopathy”, “osteopathic manipulative treatment”, “osteopathic manipulative medicine”, “OMT”, “OMM”, “manual medicine”, “chiropractic”, “massage”, “manipulation” and “spinal manipulation”

Citations Found

- Massage and Depression: 15
- OMT and Depression: 3
- Spinal manipulation and Depression: 1
- Massage and Bipolar: 1
- Chiropractic and Bipolar: 1

Massage - Depression

- 4 studies: Patient's with co-morbid condition (OA, CA, HIV, ESRD)- Decreased Depression
- 4 studies: Pregnant women - Mixed results
- 1992 Pilot Study: Inpt Psych C&A- Decreased Depression

Choi 2006, Wilkinson 2007, Fulk 2004, McDougall 2005, Field 2004, Dimidjian 2009, Field 1992

Massage - Depression

- Critical Reviews
  - 2002 - Immediate +, Long term No evidence
  - 2004 - Improvement = to psychotherapy
  - 2008 - RCTs did not support efficacy
  - 2013 - Cochrane did not support efficacy

Manber 2002, Moyer 2004, Coelho 2008, Dennis 2013

OMT - Depression

- Pilot Study: Adjunctive OMT with Paxil for Depressed Women
  - 20-50 y.o. Women, 8wks (weekly sessions)
  - Control (9): Cognitive therapy, Neurolinguistic programming, Paxil, OSE
  - Treatment (8): Same as control + OMT
    - OMS administered, Physician supervised
    - No specific OMT protocol (20 min limit)

Plotkin. JAOA. Sep 2001

OMT - Depression

- Pilot Study: Adjunctive OMT with Paxil for Depressed Women
  - Zung Depression Scale
    - Both groups significantly better
    - Control: 30% reached normal range
    - OMT: 100% reached normal range

Plotkin. JAOA. Sep 2001

OMT - Depression

- Quality of life for OMT referrals
  - SF-36 only administered
  - Lower quality of life vs controls
  - Undetermined impact of OMT on QOL

Licciardone. JAOA. Mar 2002

Mood D/O, NZ Osteopaths

- Survey of NZ Osteopaths, 29% response rate (n=62)
- 79% used manual diagnostic tools (TART, CRI)
- 62% agreed osteopathy helps mood d/o clients
- Combo(61%), Cran(53%), Struct(32%), Visceral(16%)
- 50% NZ Osteopaths- no education in Mood d/o

Sampath, IJOM, 2015

Spinal Manipulation - Depression

- Systematic review of RCT for spinal manipulation and psychological outcomes
  - Included osteopathic (2) and others
  - Small significant benefit in first 5 mo vs talking treatment

Williams. Comp Therapies in Med. 2007

Massage - Bipolar

- Review of complimentary and alternative treatment for Bipolar
  - Aromatherapy massage & Massage Therapy "almost entirely lacking" evidence

Andreescu. Jrnl Aff Dis. 2008.

Chiropractic - Bipolar

- Case Study
- Pole vaulting injury at age 17
- Over next 5 yrs - Bipolar, HA, Seizures, Insomnia
- Cervical subluxation treatment x 1
- No symptoms through 18 mo follow up

Elster. Jrn Manip & Phys There, Mar 2004

Literature Summary

- Most Evidence: Massage Therapy for Depression but mixed
- OMT: Depression Pilot study is the best evidence available

Conclusion

- Association at best for A&P of Mood Disorders
- Pilot study best evidence for OMM
- An osteopath reasons from his knowledge of anatomy - Still

Questions